

# Mechanical coil embolization of pulmonary arteriovenous malformations

Bahri Üstünsöz, Uğur Bozlar, Murat Kocaoğlu, Turan Ilica, Mehmet Dakak

## PURPOSE

To report our experience with mechanical coil embolization of pulmonary arteriovenous malformations.

## MATERIALS AND METHODS

Coil embolizations were performed in 6 men (mean age, 21.1 years; age range, 20-23 years) with pulmonary arteriovenous malformations between 1999 and 2004. Five F Cobra catheters and various sized coils were used for embolization. Clinically, cases were followed-up every 3 months for one year and every 6 months thereafter, with a mean total follow-up period of 2.3 years.

## RESULTS

Complete primary occlusion was achieved in all patients. There were no complications related to the procedure and no problems were reported during the follow-up period.

## CONCLUSION

Treatment of pulmonary arteriovenous malformation cases with coil embolization is an effective option.

*Key words:* • arteriovenous malformation • lung  
• embolization, therapeutic

**P**ulmonary arteriovenous malformations (PAVMs) are fistulous shunts of high-grade flow between the pulmonary artery and vein. More than 80% of the cases are congenital, but they may appear secondary to acquired conditions such as liver cirrhosis, schistosomiasis, mitral stenosis, trauma, actinomyces, metastatic thyroid carcinoma, and bronchiectasis (1). Approximately 70% of PAVM cases are due to hereditary hemorrhagic telangiectasia (HHT), alternatively known as Osler-Weber-Rendu disease. PAVM is encountered in 5-15% of HHT cases (2). Although telangiectasias and arteriovenous malformations (AVMs), which are primary findings in cases with PAVM and HHT, are congenital, they are usually asymptomatic until early adulthood.

PAVM is divided into two subgroups as simple and complicated types (3). In the simple type, a single feeding artery connects to a drainage vein, whereas in the complicated type, there are two or more feeding vessels and/or drainage veins. Surgery and embolotherapy are two approaches in the management of PAVM (4). The aim of this presentation is to convey our experience obtained through mechanical coil embolization treatment of 6 simple PAVM cases.

## Materials and methods

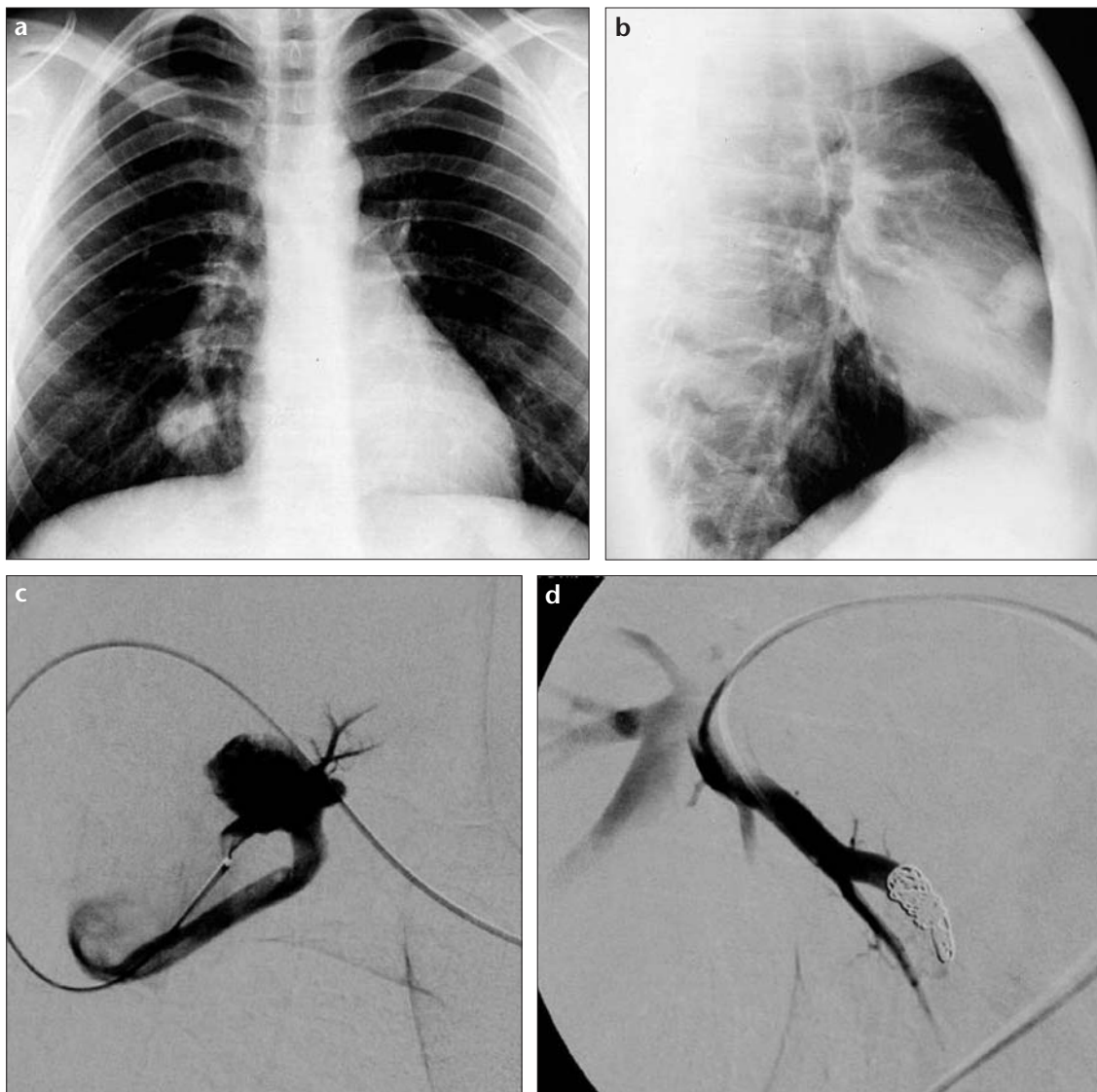
Embolotherapy was performed on 6 males with PAVMs who were asymptomatic and diagnosed first with chest radiographs that were obtained for a variety of indications while serving in the military, or during their military service health screening, later confirmed with other imaging modalities. The patients were between 20-23 years of age with a mean age of 21.1 years. After a selective pulmonary digital subtraction angiography (DSA) exam with a 5 F pigtail catheter through a 5F cobra 2 catheter (Cook, Bloomington, MA, USA), embolization was achieved using mechanical coils (Cook, Bloomington, MA, USA) that were 30% larger than the feeding artery. Clinical follow-up of the cases was performed by the related surgical clinic every three months for one year, and then every six months thereafter. Two cases were not followed-up after the first year due to completion of their military service. The other four cases were followed-up between 3 months and 4.5 years (mean, 2.3 years).

## Results

All the cases were questioned about HHT. Two cases were regarded as HHT; one case had epistaxis, and the other case had epistaxis in addition to a close relative with HHT. The liver ultrasound and cerebral computed tomography (CT) examinations of all the cases were negative for AVMs. No other gastrointestinal (GI) exams were performed for the cases, except for three consecutive fecal occult blood tests. PAVMs in all cases were the simple type, each with one feeding artery and a drainage

From the Departments of Radiology (B.Ü. ✉ [bustunsoz2000@yahoo.com](mailto:bustunsoz2000@yahoo.com), U.B., M.K., T.I.) and Thoracic Surgery (M.D.), Gülhane Military Academy of Medicine, Ankara, Turkey.

Received 20 June 2004; revision requested 2 September 2004; revision received 16 September 2004; accepted 18 September 2004.



**Figure 1.** a-d. Posteroanterior (a) and lateral (b) chest radiographs show a nodular mass in the base of the right lung which appears to be continuous with the vascular structures. In the superselective DSA examinations a PAVM in the right lobe with the feeding artery and the large drainage vein before (c) and after (d) mechanical coil embolization is seen.

vein. The diameters of the feeding arteries were 4-9 mm (mean, 5 mm). The diameters of the drainage veins were 4-7.5 mm (mean, 6 mm). Three of the cases had no venous sac. Primary occlusion was achieved during the first attempt in all cases (Figures 1 and 2). No complications related to the procedures were encountered. Clinical follow-up of the cases included physical examination, and monitoring of both exercise and resting arterial oxygen saturation and pulmonary functions. No problems were observed in the four cases during routine follow-up.

#### Discussion

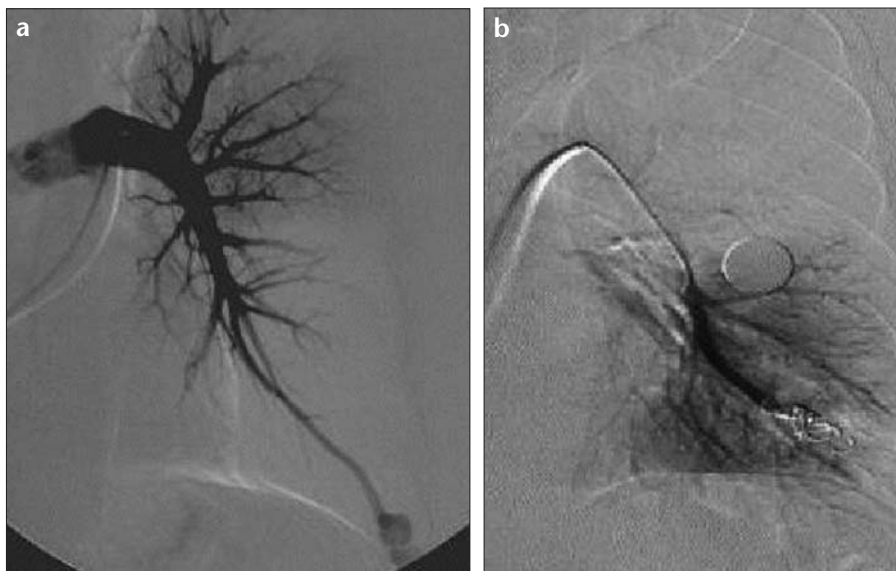
Approximately 40% of PAVM cases are diagnosed during evaluation

for etiological factors of neurological symptoms (5). Migraine attacks (43%), transient ischemic attacks (37%), stroke (18%), brain abscesses (9%) and epileptic seizures (8%) are reported as accompanying neurological symptoms (2, 5, 6). Therefore, treatment of every case with PAVM, whether symptomatic or asymptomatic, is the recommended management approach (7). For this reason, even though the cases in the present series were asymptomatic, they received embolotherapy.

Hereditary hemorrhagic telangiectasia is an autosomal dominant disorder. Approximately 70% of PAVM cases have HHT. PAVM is encountered in 5-15% of all HHT cases (2, 8). Therefore, in cases with either PAVM or HHT, the

association should be ruled out. HHT diagnosis was made in the presented series due to the presence of epistaxis history in two patients (33%). The existence of a close relative with HHT in one of the cases made the diagnosis easier. Mucocutaneous telangiectasia was not present in either of the 2 cases. The 33% ratio of cases with HHT in this series is less than what is cited in the literature, but because our cases were all relatively young, and HHT symptoms may present at a later age, this diagnosis ratio may increase as well. Another possible reason why the ratio was less than what is in the literature could be the small number of cases in the series.

Surgery was the only option in the treatment of PAVM until Taylor et al.



**Figure 2. a, b.** A PAVM is visualized in the lower lobe of the left lung with selective DSA (a), and with superselective DSA after mechanical coil embolization (b).

reported the first successful percutaneous embolization in 1978 (9). Techniques like local excision, segmental resection, lobectomy, ligation, and pneumectomy were used for the surgical treatment of PAVM (1). Moreover, surgical treatment has the risks such as surgical general anesthesia, invasiveness, the presence of more than one lesion, increased length of hospitalization and the related increases in cost and morbidity, and decreased functional reserve capacity of the lung related to the size of the resected area. In addition, if the PAVM is the complicated type, the magnitude of the intervention increases due to the increase in the number of vessels that have to be reached surgically and the increase in related volume. Furthermore, surgical indications are limited in diffuse PAVM types in which many macro- and angiographically occult microAVMs are widespread (5). For these reasons, embolotherapy is accepted as the first line of management in the treatment of PAVMs (1, 3, 6, 9-12).

Khurshid and Downie reported that separable balloons and coils are the most commonly used embolizing agents and that no difference between the two was detected regarding mortality and morbidity rates, nor results obtained (1). In the present series stainless steel mechanical coils were used as embolizing agents. Another study reported that there was no significant difference be-

tween stainless steel and platinum coils (12). These authors also mentioned that, with regard to radial force, stainless steel has more strength and could be used in fistulas with high-grade of flow, although, due to its strength, it may cause an increase in perforation and other complications.

Minor and major complications were reported in the literature secondary to embolotherapy of PAVMs (1, 3, 6, 9-12). Minor complications such as chest pain and pleurisy are encountered in 10-15% of cases. No such complications were observed in the present series. The fact that the PAVMs were the uncomplicated type and the embolized areas were small size may account for the absence of minor complications. Lung infarct and systemic coil embolization, which are considered major complications, are encountered in 4% of cases. No major complication occurred in the present series. The dual blood supply of the lungs prevents underlying ischemic infarcts if the embolized area is small. Coil migration, however, is related to technique and correct histoanatomical analysis of the PAVM. Contrary to general belief, coil migration and recanalization is encountered more often in simple PAVMs with one feeding artery and one drainage vein (6) than in complicated PAVMs because a thin, permeable capillary membrane structure is absent in simple PAVMs, but present in complicated PAVMs (10). For this reason, coil

embolization is less common in these types of cases. When PAVMs contain venous sacs, embolization of the sacs with controlled detachable coils like Guglielmi detachable coils may allow safety embolization afterwards (6). In the present series, coils 30% larger than the feeding artery were chosen to prevent coil migration. There are two basic reasons for coil recanalization. The first is embolization of a fistula that is too proximal. In this situation, development of a more distal collateral pathway not only causes recanalization, but may prevent further embolization. In the present series, the coil ball was placed in the most suitable, most distal segment of the fistula. The other cause of recanalization is placement of an insufficient amount of coils. In the present series, the coils were placed so that no contrast material blush was noted between them, and total occlusion was obtained in at least two projections in the final control DSA examinations.

The principles behind the treatment of complicated PAVMs are similar to those of the simple types. Cases in the literature related to embolization are divided into two subgroups as mentioned above and, to the best of our knowledge, there have been no reported differences regarding therapy and complications between the two subgroups (1, 3, 6, 9-12).

A situation which prompts attention is that the first embolized case was referred to the center where the procedures were conducted because of the detection of a mass lesion in the chest radiograph during a routine health examination. PAVM, if wrongly biopsied with the suspicion of a solid nodular mass, can result in catastrophic bleeding. This is important for medicolegal issues. Every case with a solitary nodule should be evaluated for PAVM to prevent catastrophic bleeding.

Although the small number of cases in the presented series precludes the broad application of the findings, we believe that embolotherapy of PAVM is superior to standard surgical treatment.

## References

1. Khurshid I, Downie GH. Pulmonary arteriovenous malformation: review. *Postgrad Med J* 2002; 78:191-197.
2. Porteous ME, Burn J, Proctor SJ: Hereditary haemorrhagic telangiectasia: a clinical analysis. *J Med Genet* 1992; 29:527-530.

3. White RI Jr, Lynch-Nyhan A, Terry P, et al. Pulmonary arteriovenous malformations: technique and long-term of embolotherapy. *Radiology* 1988; 169: 663-669.
4. Dutton JA, Jackson JE, Hughes JM, et al. Pulmonary arteriovenous malformations: results of treatment with coil embolization in 53 patients. *AJR Am J Roentgenol* 1995; 165:1119-1125.
5. Faughnan ME, Lui YW, Wirth JA, et al. Diffuse pulmonary arteriovenous malformations: characteristics and prognosis. *Chest* 2000; 117:31-38.
6. Dinkel HP, Triller J. Pulmonary arteriovenous malformations: embolotherapy with superselective coaxial catheter placement and filling of venous sac with Guglielmi detachable coils. *Radiology* 2002; 223:709-714.
7. Burke CM, Safai C, Nelson DP. Pulmonary arteriovenous malformations: a critical update. *Am Rev Respir Dis* 1986; 134:334-339.
8. Begbie ME, Wallace GMF, Shavlin CL. Hereditary haemorrhagic telangiectasia (Osler-Weber-Rendu syndrome): a view from the 21st century. *Postgrad Med J* 2002; 79:18-24.
9. Taylor BG, Cadgerill EM, Manferidi F, et al. Therapeutic embolization of the pulmonary artery in pulmonary arteriovenous fistula. *Am J Med* 1978; 64:360-365.
10. Haitjema TJ, Overtoom TT, Westermann CJ, Lammers JW. Embolization of pulmonary arteriovenous malformations: results and follow up in 32 patients. *Thorax* 1995; 50:719-723.
11. White RI Jr, Mitchell SE, Barth K, et al. Angioarchitecture of pulmonary arteriovenous malformations: an important consideration before embolotherapy. *AJR Am J Roentgenol* 1983; 140:681-686.
12. Prasad V, Chan RP, Faughnan ME. Embolotherapy of pulmonary arteriovenous malformations: efficacy of platinum versus stainless steel coils. *J Vasc Interv Radiol* 2004; 15:153-160.